

Journal Pre-proof

Capillary Density Measured by OCT Angiography in Glaucomatous Optic Disc Phenotypes

Eren Ekici, MD, Sasan Moghimi, MD, Christopher Bowd, Ph.D., Huiyuan Hou, MD, Ph.D., Rafaella C. Penteadó, MD, James Proudfoot, MSc, Diya Yang, MD, Ph.D., Robert N. Weinreb, MD

PII: S0002-9394(20)30308-1

DOI: <https://doi.org/10.1016/j.ajo.2020.06.012>

Reference: AJOPHT 11411

To appear in: *American Journal of Ophthalmology*

Received Date: 17 January 2020

Revised Date: 23 April 2020

Accepted Date: 10 June 2020

Please cite this article as: Ekici E, Moghimi S, Bowd C, Hou H, Penteadó RC, Proudfoot J, Yang D, Weinreb RN, Capillary Density Measured by OCT Angiography in Glaucomatous Optic Disc Phenotypes, *American Journal of Ophthalmology* (2020), doi: <https://doi.org/10.1016/j.ajo.2020.06.012>.

This is a PDF file of an article that has undergone enhancements after acceptance, such as the addition of a cover page and metadata, and formatting for readability, but it is not yet the definitive version of record. This version will undergo additional copyediting, typesetting and review before it is published in its final form, but we are providing this version to give early visibility of the article. Please note that, during the production process, errors may be discovered which could affect the content, and all legal disclaimers that apply to the journal pertain.

© 2020 Elsevier Inc. All rights reserved.



PURPOSE: To compare optical coherence tomography angiography (OCTA) measured capillary density of the optic disc among four glaucomatous optic disc phenotypes.

DESIGN: Cross-sectional study.

METHODS: Circumpapillary capillary density (cpCD) of four glaucomatous optic disc phenotypes in 193 eyes of 141 glaucoma patients and cpCD in 92 eyes of 55 healthy subjects from the Diagnostic Innovations in Glaucoma Study (DIGS) were compared. Areas under the receiver operating characteristic curves (AUROC) were used to evaluate diagnostic accuracy among groups after adjusting for confounders.

RESULTS: Four glaucoma phenotypes were assessed including focal ischemic (n=45), generalized cup enlargement (n=60), myopic glaucoma (n=38), and senile sclerotic (n=50). Sex, mean ocular perfusion pressure, intraocular pressure, MD, and the quality score did not differ among phenotypes. However, there were differences in age (p=0.050), race (p=0.039), axial length (p=0.033), and retinal nerve fiber layer thickness (p<0.001) among the groups. After adjusting for confounders, senile sclerotic discs had the lowest cpCD (37.1% [95% CI, 35.3–38.8]) followed by focal ischemic (41.8% [40.0 – 43.6]), myopic glaucoma (42.1% [40 – 44.2]), and generalized cup enlargement (45.5% [44 – 47]) (p<0.001) discs. The adjusted AUROC curves of cpCD for discriminating between healthy and glaucomatous eyes were highest in senile sclerotic eyes (0.928) and lowest in generalized cup enlargement eyes (0.704).

CONCLUSIONS: OCTA-measured vessel density differs among optic disc phenotypes. Clinicians should be aware that the performance of OCTA for glaucoma diagnosis may be influenced by the optic disc phenotype.

Capillary Density Measured by OCT Angiography in Glaucomatous Optic Disc Phenotypes

Eren Ekici, MD^{1,2}; Sasan Moghimi, MD¹; Christopher Bowd, Ph.D.¹; Huiyuan Hou MD, Ph.D.¹; Rafaella C. Pentado, MD¹; James Proudfoot, MSc¹; Diya Yang, MD, Ph.D.¹; Robert N. Weinreb, MD^{1*}

Running Title: OCTA and optic disc phenotypes

- 1. Hamilton Glaucoma Center, Shiley Eye Institute, Viterbi Family Department of Ophthalmology, University of California, San Diego, CA, United States.**
- 2. Ankara Ulucanlar Eye Training and Research Hospital, Department of Ophthalmology, Ankara/Turkey**

*Corresponding author: Robert N. Weinreb, Shiley Eye Institute, University of California, San Diego, La Jolla, CA 92037, email: rweinreb@ucsd.edu

Key Words: Glaucoma, OCT Angiography, optic disc phenotypes

Journal Pre-proof

INTRODUCTION

Glaucoma is an optic neuropathy characterized by progressive degeneration of retinal ganglion cells that results in a characteristic appearance of the optic disc and visual field (VF).¹ Risk factors for primary open-angle glaucoma (POAG) include increased intraocular pressure (IOP)², older age³, race⁴, disc hemorrhage (DH)⁵, and pseudoexfoliation syndrome⁶. Reduced diastolic blood pressure⁷ and decreased ocular perfusion⁸ have also been proposed to be associated with glaucomatous optic nerve injury.

It has been suggested that patterns of optic disc damage in glaucoma are related to specific pathophysiologic mechanisms. With such patterns, patients can be categorized into clinical subtypes based on the appearance of the optic disc. Nicolela and Drance^{2,3} described four optic disc phenotypes including 1) generalized enlargement (GE), 2) myopic (MY), 3) senile sclerotic (SS) and 4) focal ischemic (FI), based on clinical appearance. Various clinical features have been associated with each phenotype. For example, optic discs with generalized enlargement were associated with elevated levels of IOP, senile sclerotic optic discs were associated with systemic vascular disease, and optic discs with focal notches were associated with localized VF loss.²⁻⁵ As the rates of the visual field and optic disc change have been reported to be faster in patients with focal glaucomatous optic disc damage, it has been proposed that the classification of glaucoma by optic disc phenotype provides relevant clinical information for disease management and overall prognosis.¹²

Optical coherence tomography angiography (OCTA) is a non-invasive imaging technique that allows simultaneous *in vivo* imaging of the morphology, as well as the vasculature in the eye.⁶ Studies using OCTA have provided evidence of microvascular dropout, measured as a decrease of vessel density within the optic disc, the peripapillary retina and the macula in POAG eyes.⁷⁻⁹ Variability in vessel density has been reported in different subgroups of patients with POAG.¹⁰ POAG eyes are not homogenous with respect to vascular density, even at similar disease severities. A recent study by Suh et al¹⁰ suggested that in eyes with similar severity of VF loss, peripapillary vessel density was reduced in eyes with focal lamina cribrosa defects compared to eyes without lamina defects. Further, eyes with lamina defects at baseline show a greater loss of vessel density over time than those without (Proudfoot JA et al. IOVS 2019; 63, ARVO E-abstract #5605).

We hypothesize that each of the different optic disc appearances exhibits a unique degree and pattern of vessel density loss and that elucidating this relationship will enhance our understanding of the contributions of the ocular microcirculation and regional ocular blood flow to the pathophysiology of glaucoma, as well as the clinical management of glaucoma. The current study evaluated and compared the diagnostic performance of OCTA-measured peripapillary capillary density in four optic disc phenotypes.

METHODS

This was a cross-sectional, case-control study. Glaucoma patients and healthy subjects were recruited from the Diagnostic Innovations in Glaucoma Study (DIGS).¹⁸ DIGS is an ongoing, prospective study designed to evaluate optic nerve structure and visual function in glaucoma. Subjects have been followed regularly and monitored for glaucoma progression with comprehensive imaging since 1995. The Institutional Review Boards of the University of California San Diego approved the protocol, and the

methodology adhered to the tenets of the Declaration of Helsinki for research involving human subjects and to the Health Insurance Portability and Accountability Act. This study was registered at <http://clinicaltrials.gov> (no. NCT00221923) on September 14, 2005. Informed consent was obtained from all participants.

Methodological details of DIGS have been described previously.¹¹ In brief, all the subjects underwent an annually comprehensive ophthalmologic examination, including best-corrected visual acuity, slit-lamp biomicroscopy, IOP measurement with Goldmann applanation tonometry, gonioscopy, dilated fundus examination, stereoscopic optic disc photography, ultrasound pachymetry and central corneal thickness (CCT) measurements in both eyes. Semiannual examination included IOP, OCT imaging, and standard automated perimetry (SAP) testing. Participants underwent extensive clinical examinations.

Inclusion criteria for this study¹¹ were open angles with gonioscopy, best-corrected visual acuity of 20/40 or better, and refraction less than 5.0 diopters sphere and 3.0 diopters cylinder. Participants with a history of intraocular surgery (except for uncomplicated cataract surgery or uncomplicated glaucoma surgery), retinal pathologies including diabetic retinopathy and hypertensive retinopathy, non-glaucomatous optic neuropathy, uveitis, ocular trauma, Parkinson disease, Alzheimer disease, or stroke affecting visual field were excluded. Other information including race, age, non-ocular disease history, blood pressure (BP), and central corneal thickness (CCT) also was collected. Mean arterial pressure was calculated as $(1/3 \text{ systolic BP} + 2/3 \text{ diastolic BP})$. Mean ocular perfusion pressure (MOPP) was defined as the difference between two-thirds of mean arterial pressure and IOP.

Healthy subjects had bilateral 1) IOP < 21 mm Hg with no history of elevated IOP; 2) normal-appearing optic disc, intact neuroretinal rim and retinal nerve fiber layer (RNFL); and 3) a minimum of 2 reliable normal VF (defined as a pattern standard deviation (PSD) within 95% confidence limits and a glaucoma hemifield test (GHT) result within normal limits).¹² POAG patients were defined as individuals who had reliable (<33% fixation losses and false-negative results and <15% false-positive results) and at least 2 consecutive abnormal standard automated perimetry tests with the Humphrey 24-2 Swedish Interactive Threshold Algorithm with PSD outside the 95% normal limits or GHT results outside normal limits with similar patterns of the defect.¹²

All color simultaneous stereophotographs were acquired using a Nidek Stereo Camera Model 3-DX (Nidek Inc, Palo Alto, CA) after maximal pupil dilation. Photograph evaluations were performed using a simultaneous stereoscopic viewer (Asahi Pentax Stereo Viewer II; Pentax, Tokyo, Japan) with a standard fluorescent light bulb. In eyes with POAG, disc types were classified by allocating stereophotographs into four distinct phenotypes as described by Nicoleta and Drance as well as a mixed or unclassified phenotypes:^{4,9} (Figure 1) With generalized cup enlargement (GE), there was large and deep concentric circular cupping without a localized defect of the neuroretinal rim. With focal ischemic (FI), the optic disc had a circular disc and focal loss of nerve fibers within the neuroretinal rim, and the other areas were normal. With myopic glaucomatous (MY), there was temporal parapapillary atrophy with temporal cupping and the optic disc was slightly tilted and ellipsoid. And with senile sclerotic (SS), there was an atrophic halo (chorioretinal atrophy) around the optic disc, saucerized and shallow cupping, and a 'moth-eaten' and pale appearance of the neuroretinal rim. For a combination of optic disc phenotypes, the optic discs were classified as mixed. Two glaucoma specialists (E.E., S.M.), who were masked to the participant's identity, diagnostic status, race, and other results, classified independently the disc types

based on the photographs. If their classification did not agree, the consensus was obtained after the photographs were reviewed again. Any optic disc in which consensus could not be reached was categorized as unclassified. Mixed or unclassified eyes (n =61) were not included in the statistical analysis.

Optical Coherence Tomography Angiography

The OCT AngioVue system (Optovue Inc., Fremont, CA, USA) incorporated in the Avanti SD-OCT system was used for characterizing the circumpapillary retinal nerve fiber layer thickness (cpRNFL) and vascular structures of the retina at the capillary level (using software version 2017 1.0.144). This system has been described previously.¹³

Capillary density within the cpRNFL was measured from the internal limiting membrane (ILM) to the RNFL posterior boundary after the removal of large vessels. Whole enface image capillary density (wiCD) was measured in the entire 4.5×4.5 mm² image, and circumpapillary capillary density (cpCD) was calculated in the region defined as a 750µm-wide elliptical annulus extending from the optic disc boundary-based. Measurements were analyzed using six sectors, as described by Garway Heath et al.¹⁴

Poor quality images, defined as those with 1) a signal quality (SQ) of less than 4, 2) poor clarity, 3) motion artifacts visible as irregular vessel patterns or disc boundaries on the enface angiogram, 4) local weak signal, or 5) segmentation errors, were excluded. The location of the disc margin was reviewed for accuracy and adjusted manually if required.

Statistical Analysis

Statistical analyses were performed using STATA software version 15.0 (StataCorp, College Station, TX) and R software version 3.3.1 (R Foundation, Vienna, Austria). Statistical significance for tests was set at $P \leq 0.05$. Descriptive statistics were calculated as the mean and 95 % confidence interval. Categorical variables were compared using the chi-square test. Mixed-effects modeling was used to compare ocular parameters among phenotypes. Models were fitted with ocular measurements (including OCTA parameters) as the response variable and the classification group as fixed effects. Measurements of bilateral eyes were nested within-subject to account for the fact that eyes from the same individual are more likely to have similar measurements.^{15, 16} Multivariable models were constructed including the following potential confounding factors: age, gender, scan quality (SQ), axial length, visual field mean deviation (VF MD), in addition to any other ocular parameters for which the P -value was < 0.1 in univariate analysis. Also, factors affecting capillary density were examined using a univariate and multivariable linear mixed model.

Percentage loss of capillary density in the glaucomatous eyes relative to capillary density in the healthy group was calculated for each phenotype similar to the method of Zhang et al.¹⁷ and depicted using heat map plots. Marginal effect estimates from mixed-effects models fit to healthy subjects (with a random intercept to account for within-subject correlation and adjusting for age and SQ as fixed factors) were used to determine expected capillary densities for each sector.

*Estimated percentage capillary density loss= [(expected vessel density - observed vessel density)/ expected vessel density]*100*

Diagnostic accuracy for differentiating between healthy and glaucoma eyes was evaluated by calculating the area under the receiver operating characteristic (AUROC) curves for each phenotype and compared. AUROCs also were adjusted for age, SQ, axial length and, disease severity (VF MD) using a covariate adjustment regression method.¹⁸

RESULTS

92 eyes of 55 healthy subjects and 193 eyes of 141 glaucoma patients with good-quality scans were included in the analysis. The inter-examiner agreement of classification into the generalized enlargement, focal ischemic, myopic glaucoma, senile sclerotic, mixed, or unclassified disc appearance type was good with a Kappa value of 0.847 (0.821 - 0.891).

Differences in age, gender, history of hypertension (HT), history of diabetes mellitus (DM) between healthy and glaucomatous study participants and differences between axial length (AL), CCT, IOP, VF MD, VF PSD, and RNFL thickness between healthy and glaucomatous eyes are shown in Table 1. In the glaucoma group, 32 (22.7%), 98 (69.5%), 10 (7.1%), and 1 (0.7 %) were subjects of African descent, European descent, and Asian descent, and other ethnicities respectively. In the healthy group, 16 (29.1%), 4 (7.3%), 33 (60%), and 2 (3.7%) were subjects of African descent, European descent, Asian descent, and other ethnicities, respectively. Glaucoma participants were older and had a more self-reported history of HT and DM than healthy participants ($p < 0.05$ for all). Glaucoma eyes had lower CCT, cpCD, wiCD, sectoral vessel densities, and cpRNFL thicknesses compared to healthy eyes ($p < 0.05$ for all). There were no significant differences among the groups in terms of race, systolic BP or diastolic BP, MOPP.

Among 193 glaucomatous eyes, the optic discs of 45 eyes were classified as focal ischemic, 60 eyes as generalized enlargement, 38 eyes as myopic glaucoma, and 50 eyes as senile sclerotic (Table 1). Individuals in the senile sclerotic group were older. The senile sclerotic group and myopic glaucomatous eyes were more frequently non-African American. Although myopic eyes had the longest axial length, cpRNFL and VF MD were the lowest in the senile sclerotic group.

Generalized enlargement eyes had the greatest wiCD (43.8 % [95% CI, 42.5 – 45.1]) and cpCD (45.5 % [95% CI, 44 – 47]), whereas senile sclerotic eyes had the lowest wiCD (37.5 % [95% CI, 36.1 – 38.9]) and cpCD (37.1 % [95% CI, 35.3 – 38.8]) ($p < 0.001$). Myopic glaucoma eyes had comparable wiCD (41.4 % [95% CI, 39.7 – 43.1]) vs. 41.1 % [95% CI, 39.4 – 42.7], ($p = 0.785$) and cpCD (42.1 % [95% CI, 40 – 44.2]) vs. 41.8 % [95% CI, 40 – 43.6], ($p = 0.828$) as focal ischemic eyes. Similar results were found for sectoral vessel density parameters. Results were similar after adjusting vessel density parameters for age, gender, axial length, VF MD and SQ (Table 2).

Figure 2 depicts the estimated percentage loss of vessel density in each optic disc phenotype. A different pattern of vessel density loss was found among the groups. A diffuse pattern of vessel density loss was found in generalized enlargement while the infratemporal sector was the most affected region in the myopic glaucoma group. In the focal ischemic and senile sclerotic groups, inferior sectors were affected more than the other sectors. Temporal and nasal sectors were less affected in all optic disc phenotypes.

Factors associated with cpCD among glaucomatous eyes are presented in Table 3. In univariate analysis male gender ($p=0.016$), non-African American ($p<0.001$), lower IOP ($p=0.013$), lower VF MD ($p<0.001$) and lower cpRNFL ($p<0.001$) were associated with lower vessel density. The senile sclerotic phenotype was associated with lower cpCD in both univariate ($P<0.05$ for all pairwise comparison) and multivariable analyses ($p<0.05$ for all pairwise comparison). Older age ($p=0.035$), male sex ($p<0.001$), DH ($p=0.004$), lower VF MD ($p<0.001$) and lower cpRNFL ($p<0.001$) also were associated with lower vessel density in multivariable analyses.

Figure 3 demonstrates the adjusted and unadjusted AUROC curves of peripapillary capillary density for discriminating glaucomatous from healthy eyes among different phenotypes. The unadjusted AUROC curves of cpCD for discriminating between healthy and glaucomatous eyes were the highest in senile sclerotic eyes [AUROC: 0.984 (0.961, 1.000)]. The unadjusted AUROC curve of cpCD was lower in generalized enlargement eyes [AUROC: 0.749 (0.667, 0.831)] compared to senile sclerotic eyes ($p<0.001$), focal ischemic eyes [AUROC: 0.927 (0.883, 0.972), $p<0.011$], and myopic eyes [AUROC: 0.875 (0.809, 0.941), $p=0.034$]. A similar result was found when adjusting the AUROC curves for age, axial length, VF MD and SQ.

DISCUSSION

The present study evaluated peripapillary vessel density in four distinct glaucomatous optic disc phenotypes and demonstrated differences in vessel density loss and patterns among the groups. Eyes with a senile sclerotic disc appearance had lower vessel density and those with generalized enlargement of the cup had greater vessel density before and after adjustment for age, glaucoma severity and scan quality. The discriminating ability (defined as AUROCs) of OCTA parameters to detect glaucoma was affected by optic disc phenotypes and was greatest for the senile sclerotic optic disc phenotype. Geijssen and Greve¹⁹ suggested that senile sclerotic changes likely indicate a systemic vascular abnormality that may be age-related which could lead to chronic ischemia of the optic disc.^{2, 3, 20, 21} This chronic ischemia could also explain the marked peripapillary atrophy and choroidal thinning found in these patients.^{22, 23} Nicola et al. have reported that patients with senile sclerotic discs have greater circulatory changes in their retrobulbar vessels, as measured with color Doppler imaging.²¹ Patients with glaucomatous senile sclerotic discs were usually elderly with a higher prevalence of microvascular disease manifesting as ischemic heart disease or systemic hypertension.² The current results suggest that a senile sclerotic disc appearance is an independent risk factor for lower vessel density even after adjusting for age, glaucoma severity and other confounders.

In a recent report, peripapillary vessel density was shown to be an independent predictor of glaucoma progression in open-angle glaucoma eyes.²⁴ In a longitudinal study by Reis et al., VF progression was faster in eyes with focal optic disc damage than in eyes with senile sclerotic and diffuse damage with a similar amount of IOP reduction over a mean follow-up of 3.5 years.⁵ They postulate that patients with different patterns of optic disc damage might have different sensitivities to IOP reduction. IOP-independent factors like reduced optic disc blood flow might have an important role in the progression of senile sclerotic subtypes, a hypothesis that was supported by our findings.⁵

Earlier studies have shown that patients with glaucoma associated with generalized cup enlargement were younger and had significantly higher pretreatment maximal IOP levels and higher mean IOP values than patients from the other subgroups.³ More concentric enlargement of the optic cup develops in some

patients, particularly in those with elevated IOP. This is usually associated with diffuse thinning of the retinal nerve fiber layer.² Cup deepening, perhaps a combination effect of neuroretinal tissue loss and posterior displacement of the lamina cribrosa, usually is most noticeable when associated with generalized cup enlargement. It is considered that in generalized cup enlargement, pressure-related factors play an important role and this subtype of POAG should respond well to IOP reduction.³ Deokule et al.²⁵ studied the 24-hour pattern of intraocular pressure (IOP) with different glaucomatous optic disc appearances and found that a concentric optic disc appearance was associated with higher nocturnal IOP than non-concentric optic disc appearance. Other investigators also found fewer disc hemorrhages in the generalized cup enlargement group compared to the focal ischemic and senile sclerotic groups.³² These findings also were supported by the lower performance of OCTA in detecting glaucoma in the generalized enlargement group compared to the senile sclerotic group, even after adjusting confounders.

Prior studies demonstrated that the relationship between vessel density and VF measures also is complex and influenced by many factors.²⁶⁻²⁸ In the current study we found that older age, male gender, non-African American descent, DH, lower VF MD, lower cpRNFL and senile sclerotic phenotypes were associated with lower vessel density measurements in the glaucoma group. Likewise, a significant correlation was found between the OCTA parameters and VF MD, between OCTA parameters and the glaucoma stage by other investigators.²⁸⁻³⁰ The majority of the studies that assess OCTA measurements in POAG and normal eyes have also shown older age to be associated with lower macular and peripapillary vessel density.^{24, 31-33} These studies reported that peripapillary vessel density was higher in female subjects^{24, 31-33} which is consistent with the current study. In a cross-sectional study of POAG eyes with or without DH, Rao et al.³⁴ found peripapillary vessel density was lower in sectors with disc hemorrhage compared to those without disc hemorrhage. In the present study, in univariate analysis, non-African American descent was associated with lower vessel density. Nevertheless, the senile sclerotic phenotype was an independent factor for low vessel density in multivariate analyses suggesting that the optic nerve phenotype provides useful information for diagnosing and assessing the prognosis of glaucoma. The diffuse pattern of vessel density loss was found in generalized enlargement, while myopic glaucoma and focal ischemic had more localized vessel density loss. This is in line with our finding that VF PSD was greater in generalized enlargement phenotype, mirroring more localized glaucoma damage in the latter two groups. Similarly, earlier studies showed that focal ischemic and myopic glaucoma discs are more associated with localized VF defects while generalized enlargement and senile sclerotic are more associated with diffuse VF defects.^{2, 20}

There are several limitations to the current study. First, optic disc phenotype diagnoses were based on subjective observation; however, this limitation was addressed at least in part by having two experienced graders determine the optic disc phenotype and by the good inter-observer agreement in determining the final optic disc phenotype ($\kappa = 0.84$). Another limitation is that there is evidence that ocular hypotensive eye drops might affect ocular blood flow.^{35, 36} Although the number of patients using topical glaucoma medications was similar in the four glaucomatous optic disc phenotypes groups, some patients were receiving multiple eye drops and the overall use of topical medications in the four groups was different. Therefore, we cannot entirely exclude the possibility that the ocular hypotensive drops could be responsible for the vascular differences among groups. Moreover, the phenotypes were not similar in many ocular and demographic characteristics and multivariable analysis may not be adequate to control all the factors that might affect vessel density measurements. Although eyes with axial length greater than 26.5 mm were not included in the present study, the measurement error induced by axial length variation cannot be ruled out.³⁷ Finally, the effect of parapapillary atrophy on superficial vessel density

measurement cannot be ruled out and it is possible that reduced vessel density is a secondary phenomenon in these eyes. Longitudinal studies are needed to better understand if reduced vessel density is a primary event or secondary event in eyes with the senile sclerotic optic disc phenotype.

In conclusion, our results show that the discriminating ability of OCTA parameters to detect glaucoma was affected by optic disc phenotype. Thus, clinicians should be aware that the performance of OCTA for glaucoma diagnosis may be influenced by the optic disc phenotype, and this should be taken into account when evaluating patients for glaucoma.

Journal Pre-proof

Acknowledgments:

FUNDING/SUPPORT: Supported in part by National Institutes of Health/National Eye Institute grants R01 EY029058 (RNW), R21 EY027945 (CB); by core grant P30EY022589; by an unrestricted grant from Research to Prevent Blindness (New York, NY); by grants for participants' glaucoma medications from Alcon, Allergan, Pfizer, Merck, and Santen, and by the donors of the National Glaucoma Research Program, a program of the BrightFocus Foundation.

Financial Disclosure: **E. Ekici**, None; **S. Moghimi**, None; **Huiyuan Hou**, None; **Rafaella Pentead**, None; **James Proudfoot**, None; **Cristopher Bowd**, None; **D. Yang**: None; **R.N. Weinreb**, Heidelberg Engineering (F), Carl Zeiss Meditec (F, R), Konan (F), National Eye Institute (F), Optovue (F), Allergan (C), Bausch&Lomb (C,F), Eyenovia (C), Novartis (C)

REFERENCES

1. Weinreb RN, Aung T, Medeiros FA. The pathophysiology and treatment of glaucoma: a review. *JAMA* 2014;311:1901-11.
2. Nicolela MT, Drance SM. Various glaucomatous optic nerve appearances: clinical correlations. *Ophthalmology* 1996;103:640-649.
3. Broadway DC, Nicolela MT, Drance SM. Optic disk appearances in primary open-angle glaucoma. *Surv Ophthalmol* 1999;43 Suppl 1:S223-43.
4. Nicolela MT, McCormick TA, Drance SM, Ferrier SN, LeBlanc RP, Chauhan BC. Visual field and optic disc progression in patients with different types of optic disc damage. *Ophthalmology* 2003;110:2178-2184.
5. Reis AS, Artes PH, Belliveau AC, et al. Rates of change in the visual field and optic disc in patients with distinct patterns of glaucomatous optic disc damage. *Ophthalmology* 2012;119:294-303.
6. Ang M, Tan ACS, Cheung CMG, et al. Optical coherence tomography angiography: a review of current and future clinical applications. *Graefes Arch Clin Exp Ophthalmol* 2018;256:237-245.
7. Schuman JS. Measuring Blood Flow: So What? *JAMA ophthalmology* 2015;133:1052-3.
8. Yarmohammadi A, Zangwill LM, Diniz-Filho A, et al. Optical coherence tomography angiography vessel density in healthy, glaucoma suspect, and glaucoma eyes. *Investigative ophthalmology & visual science* 2016;57:OCT451-OCT459.
9. Yarmohammadi A, Zangwill LM, Diniz-Filho A, et al. Peripapillary and macular vessel density in patients with glaucoma and single-hemifield visual field defect. *Ophthalmology* 2017;124:709-719.
10. Suh MH, Zangwill LM, Manalastas PI, et al. Optical Coherence Tomography Angiography Vessel Density in Glaucomatous Eyes with Focal Lamina Cribrosa Defects. *Ophthalmology* 2016;123:2309-2317.
11. Sample PA, Girkin CA, Zangwill LM, et al. The African Descent and Glaucoma Evaluation Study (ADAGES): design and baseline data. *Arch Ophthalmol* 2009;127:1136-45.
12. Yarmohammadi A, Zangwill LM, Diniz-Filho A, et al. Optical Coherence Tomography Angiography Vessel Density in Healthy, Glaucoma Suspect, and Glaucoma Eyes. *Invest Ophthalmol Vis Sci* 2016;57:OCT451-9.
13. Jia Y, Tan O, Tokayer J, et al. Split-spectrum amplitude-decorrelation angiography with optical coherence tomography. *Opt Express* 2012;20:4710-25.
14. Garway-Heath DF, Holder GE, Fitzke FW, Hitchings RA. Relationship between electrophysiological, psychophysical, and anatomical measurements in glaucoma. *Invest Ophth Vis Sci* 2002;43:2213-2220.
15. Alencar LM, Zangwill LM, Weinreb RN, et al. A comparison of rates of change in neuroretinal rim area and retinal nerve fiber layer thickness in progressive glaucoma. *Invest Ophth Vis Sci* 2010;51:3531-9.
16. Medeiros FA, Alencar LM, Zangwill LM, et al. Detection of Progressive Retinal Nerve Fiber Layer Loss in Glaucoma Using Scanning Laser Polarimetry with Variable Corneal Compensation. *Invest Ophth Vis Sci* 2009;50:1675-1681.

17. Zhang C, Tatham AJ, Abe RY, et al. Macular Ganglion Cell Inner Plexiform Layer Thickness in Glaucomatous Eyes with Localized Retinal Nerve Fiber Layer Defects. *PLoS One* 2016;11:e0160549.
18. Pepe M, Longton G, Janes H. Estimation and Comparison of Receiver Operating Characteristic Curves. *Stata J* 2009;9:1.
19. Geijssen HC, Greve EL. The spectrum of primary open angle glaucoma. I: Senile sclerotic glaucoma versus high tension glaucoma. *Ophthalmic Surg* 1987;18:207-13.
20. Broadway DC, Drance SM. Glaucoma and vasospasm. *Br J Ophthalmol* 1998;82:862-70.
21. Nicolela MT, Walman BE, Buckley AR, Drance SM. Various glaucomatous optic nerve appearances - A color Doppler imaging study of retrobulbar circulation. *Ophthalmology* 1996;103:1670-1679.
22. Sarks SH. Senile choroidal sclerosis. *Br J Ophthalmol* 1973;57:98-109.
23. Roberts KF, Artes PH, O'Leary N, et al. Peripapillary choroidal thickness in healthy controls and patients with focal, diffuse, and sclerotic glaucomatous optic disc damage. *Arch Ophthalmol* 2012;130:980-6.
24. Moghimi S, Zangwill LM, Penteado RC, et al. Macular and Optic Nerve Head Vessel Density and Progressive Retinal Nerve Fiber Layer Loss in Glaucoma. *Ophthalmology* 2018;125:1720-1728.
25. Deokule SP, Doshi A, Vizzeri G, et al. Relationship of the 24-hour pattern of intraocular pressure with optic disc appearance in primary open-angle glaucoma. *Ophthalmology* 2009;116:833-839.
26. Chen HS, Liu CH, Wu WC, Tseng HJ, Lee YS. Optical Coherence Tomography Angiography of the Superficial Microvasculature in the Macular and Peripapillary Areas in Glaucomatous and Healthy Eyes. *Invest Ophthalm Vis Sci* 2017;58:3637-3645.
27. Rao HL, Pradhan ZS, Weinreb RN, et al. Relationship of Optic Nerve Structure and Function to Peripapillary Vessel Density Measurements of Optical Coherence Tomography Angiography in Glaucoma. *J Glaucoma* 2017;26:548-554.
28. Yarmohammadi A, Zangwill LM, Diniz-Filho A, et al. Relationship between Optical Coherence Tomography Angiography Vessel Density and Severity of Visual Field Loss in Glaucoma. *Ophthalmology* 2016;123:2498-2508.
29. Jia Y, Wei E, Wang X, et al. Optical coherence tomography angiography of optic disc perfusion in glaucoma. *Ophthalmology* 2014;121:1322-32.
30. Liu L, Jia Y, Takusagawa HL, et al. Optical Coherence Tomography Angiography of the Peripapillary Retina in Glaucoma. *JAMA Ophthalmol* 2015;133:1045-52.
31. Shoji T, Zangwill LM, Akagi T, et al. Progressive Macula Vessel Density Loss in Primary Open-Angle Glaucoma: A Longitudinal Study. *Am J Ophthalmol* 2017;182:107-117.
32. Hou H, Moghimi S, Zangwill LM, et al. Macula Vessel Density and Thickness in Early Primary Open-Angle Glaucoma. *Am J Ophthalmol* 2019;199:120-132.
33. Penteado RC, Zangwill LM, Daga FB, et al. Optical Coherence Tomography Angiography Macular Vascular Density Measurements and the Central 10-2 Visual Field in Glaucoma. *J Glaucoma* 2018;27:481-489.
34. Rao HL, Pradhan ZS, Weinreb RN, et al. Optical Coherence Tomography Angiography Vessel Density Measurements in Eyes With Primary Open-Angle Glaucoma and Disc Hemorrhage. *J Glaucoma* 2017;26:888-895.

35. Feke GT, Bex PJ, Taylor CP, et al. Effect of brimonidine on retinal vascular autoregulation and short-term visual function in normal tension glaucoma. *Am J Ophthalmol* 2014;158:105-112 e1.
36. Siesky B, Harris A, Brizendine E, et al. Literature review and meta-analysis of topical carbonic anhydrase inhibitors and ocular blood flow. *Surv Ophthalmol* 2009;54:33-46.
37. Sampson DM, Gong PJ, An D, et al. Axial Length Variation Impacts on Superficial Retinal Vessel Density and Foveal Avascular Zone Area Measurements Using Optical Coherence Tomography Angiography. *Invest Ophth Vis Sci* 2017;58:3065-3072.

Journal Pre-proof

Figures

Figure 1: Glaucomatous optic disc types classified into four groups as described by Nicolela and Drance.

Figure 2: The estimated percentage loss of capillary density in four distinct optic disc phenotypes. (FI) focal ischemic, (GE) generalized cup enlargement, (MY) myopic glaucomatous, and (SS) senile sclerotic.

Figure 3: Unadjusted (left) and adjusted area under the curves of peripapillary capillary density (right) for discriminating glaucomatous from healthy eyes in different phenotypes. (FI) focal ischemic, (GE) generalized cup enlargement, (MY) myopic glaucomatous, and (SS) senile sclerotic.

	Glaucoma	Healthy	P-value	GE	FI	MY	SS	P-value
N (eye)	141(193)	55(92)	-	46 (60)	36(45)	24(38)	35(50)	-
Age (years)	71.6 (10.4, 70.1)	64.9 (62.4, 67.5)	<0.001	69.8 (66.8, 72.8)	71.1 (68.4, 73.7)	71.4 (67.6, 75.3)	75.9 (71.7, 80.2)	0.050 §¶
Gender (male/female)	74/67	13/42	<0.001	28/18	14/22	11/13	21/14	0.159
History of Hypertension, n (%)	79 (56.0)	20 (36.3)	0.013	28 (60.9)	19 (52.8)	12 (50.0)	20 (57.1)	0.810
Race Non-African American/ African American	109 /32	38/16	0.314	29/17	29/7	21/3	30/5	0.039
Diastolic BP (mmHg)	78.7 (12, 76.7)	78.3 (75.5, 81.1)	0.844	79.8 (76.4, 83.3)	80.9 (76.5, 85.3)	75.2 (69.9, 80.5)	77.3 (73.5, 81)	0.252
Systolic BP (mmHg)	128.5 (17.5, 125.6)	128 (123.8, 132.2)	0.849	130.5 (125.6, 135.5)	129.2 (122.5, 135.9)	122.3 (114.3, 130.2)	129.4 (124.4, 134.5)	0.281
History Diabetes Mellitus, n (%)	24 (17.0)	3 (5.4)	0.035	10 (21.7)	5 (13.8)	3 (12.5)	6 (17.1)	0.724
MOPP (mmHg)	53.9 (52.7, 55.1)	53.4 (52, 54.7)	0.626	54.9 (52.6, 57.1)	55.2 (52.3, 58.2)	51.4 (48.7, 54.1)	53.4 (51.3, 55.4)	0.156 ‡
AL (mm)	24.2 (24, 24.4)	23.7 (23.4, 23.9)	0.002	24 (23.7, 24.2)	24 (23.6, 24.4)	24.9 (24.3, 25.4)	24.1 (23.8, 24.5)	0.033 † #
CCT (µm)	533.8 (527.4, 540.1)	548.8 (541.6, 556.1)	0.014	531.7 (521.5, 541.9)	531.5 (519.9, 543)	537.1 (519.7, 554.5)	535.7 (521.8, 549.6)	0.937
IOP (mmHg)	13.7 (13.1, 14.3)	15.2 (14.6, 15.8)	0.002	14.4 (13.3, 15.5)	13.2 (12, 14.4)	12.6 (11.4, 13.9)	14.1 (12.7, 15.5)	0.195
Disc Hemorrhage, n (%)	9 (4.6)	0 (0)	0.035	2 (3.3)	2 (4.4)	1 (2.63)	4 (8)	0.604
VF MD (dB)	-5.7 (-6.5, -4.9)	-0.1 (-0.4, 0.3)	<0.001	-4.2 (-5.6, -2.9)	-5.6 (-7.2, -3.9)	-6.4 (-8.2, -4.6)	-7.1 (-8.8, -5.3)	0.082 §
cpRNFL (µm)	72.6 (70.5, 74.8)	98.4 (96, 100.7)	<0.001 (<0.001)	81.5 (77.5, 85.4)	70.6 (66.7, 74.4)	64.3 (60.8, 67.8)	72.3 (67.6, 77)	<0.001 †‡§¶ # <0.001 †‡§#
Abbreviations: AL, axial length; BP, blood pressure; CCT, central corneal thickness; cpCD, circumpapillary capillary density; cpRNFL, circumpapillary retinal nerve fiber layer; dB, decibels; FI, focal ischemic; GE, generalized cup enlargement; IOP, intraocular pressure; MD, mean deviation; MOPP, mean ocular perfusion pressure; MY, myopic glaucomatous; PSD, pattern standard deviation; SS, senile sclerotic disc; VF, visual field; wiCD, whole image capillary density.								
Tukey honestly significant difference test $P < 0.05$ for: † GE vs. FI; ‡ GE vs MY; § GE vs SS; MY vs FI; ¶ SS vs FI; # SS vs MY.								

Table 1: Demographics and Clinical Characteristics of 285 Eyes of 196 Subjects

Journal Pre-proof

Table 2: Comparison of Vessel Density in Groups between Healthy and Glaucomatous Optic Disc Phenotypes

	Glaucoma (No=143, Eye=228)	Healthy (No=56, Eye=98)	P-value (Adjusted)	GE 46 (60)	FI 36(45)	SS 24(38)	MY 35(50)	P-value (Adjusted)
wiCD (%)	41 (40.3, 41.8)	48.6 (48, 49.2)	<0.001 (<0.001)	43.8 (42.5, 45.1)	41.1 (39.4, 42.7)	37.5 (36.1, 38.9)	41.4 (39.7, 43.1)	<0.001 †‡§¶# (<0.001) §¶#

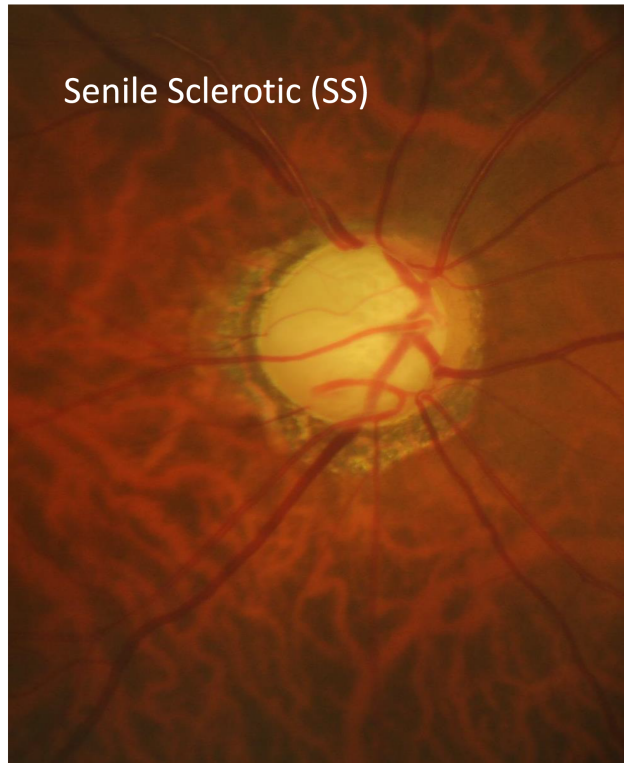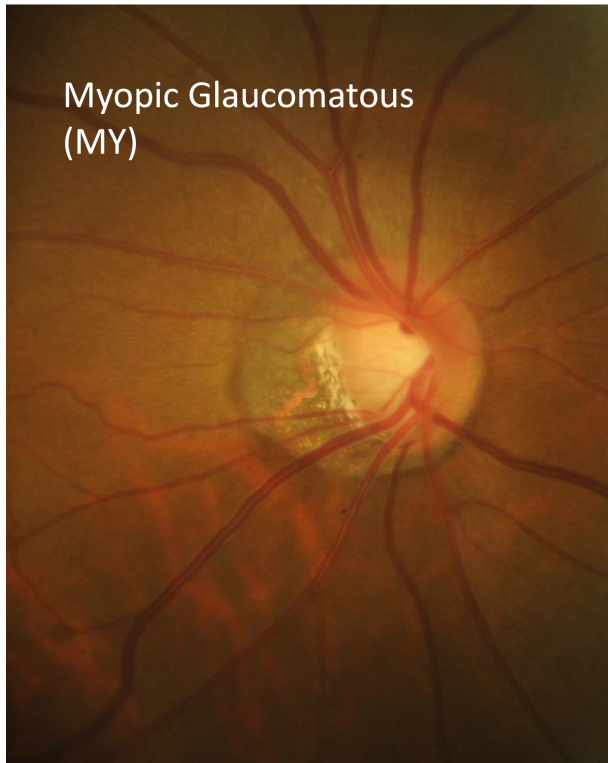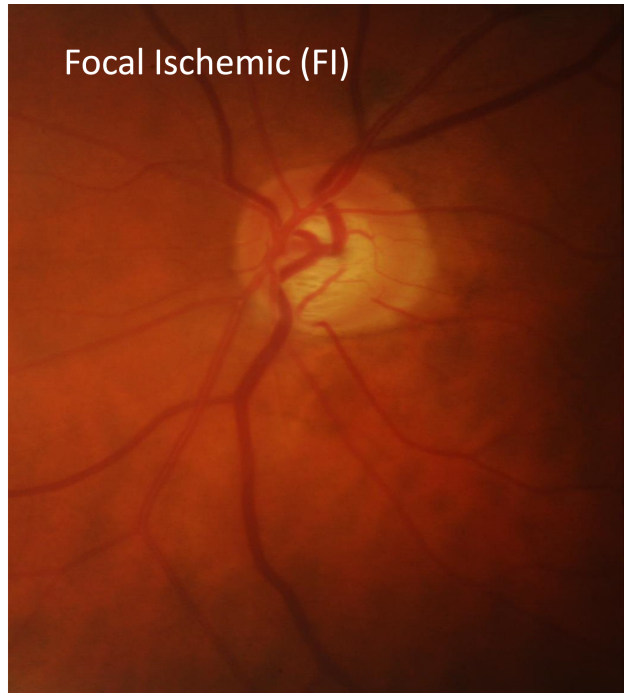
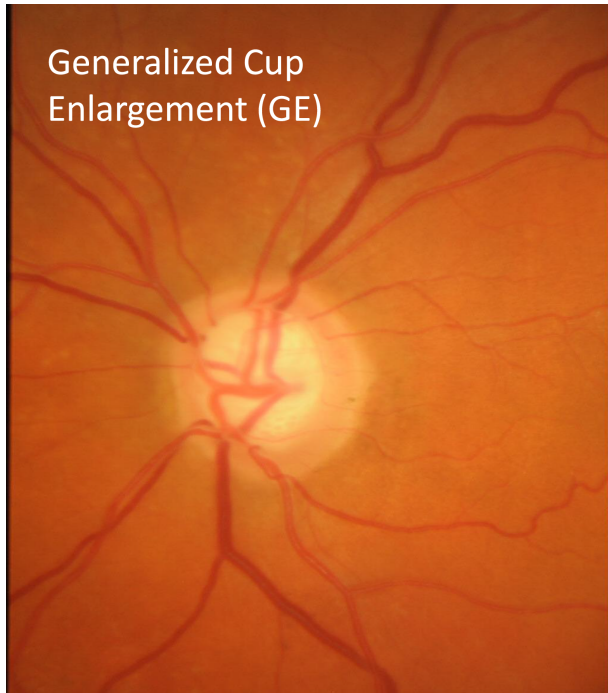
cpCD (%)	41.8 (40.8, 42.8)	50.4 (49.8, 51.1)	<0.001 (<0.001)	45.5 (44, 47)	41.8 (40, 43.6)	37.1 (35.3, 38.8)	42.1 (40, 44.2)	<0.001 †‡§¶# (<0.001) †§¶#
Nasal	39.8 (38.7, 40.8)	47.4 (46.4, 48.3)	<0.001 (<0.001)	43.5 (41.9, 45.2)	39.6 (37.7, 41.6)	35.1 (33, 37.3)	40.2 (37.9, 42.5)	<0.001 †‡§¶# (0.014) †§¶#
Temporal	49 (48.1, 49.9)	54 (53.3, 54.7)	<0.001 (<0.001)	50.6 (49.1, 52)	50.8 (49, 52.6)	45.2 (43.3, 47.1)	49.5 (47.5, 51.5)	<0.001 §¶# (<0.001) §¶#
Inferonasal	36.9 (35.6, 38.3)	47.8 (46.8, 48.8)	<0.001 (<0.001)	42.2 (39.9, 44.5)	35 (32.4, 37.6)	31.6 (29, 34.2)	37.8 (35.3, 40.3)	<0.001 †‡§# (<0.001) †§ #
Inferotemporal	41 (39.2, 42.9)	55.6 (54.7, 56.5)	<0.001 (<0.001)	47.6 (44.9, 50.2)	39.9 (36.4, 43.4)	36 (32.4, 39.6)	38.7 (33.9, 43.5)	<0.001 †‡§ (0.020) †§
Supratemporal	41.2 (39.8, 42.7)	52.8 (51.8, 53.7)	<0.001 (<0.001)	45.7 (43.5, 47.9)	41.3 (38.3, 44.4)	35.3 (32.6, 38)	42 (38.1, 45.8)	<0.001 †§¶# (<0.001) §¶#
Supranasal	37.6 (36.3, 38.8)	46.6 (45.8, 47.4)	<0.001 (<0.001)	40.9 (38.8, 43.1)	37.3 (34.7, 39.8)	32.7 (30.5, 34.9)	39 (36, 42)	<0.001 †§¶# (0.006) §#
Quality Score	6.7 (6.6, 6.9)	7.4 (7.2, 7.6)	<0.001	7.0 (6.7, 7.2)	6.8 (6.5, 7.2)	6.5 (6.1, 6.8)	6.7 (6.3, 7)	0.198

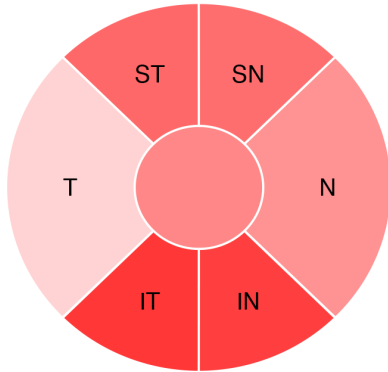
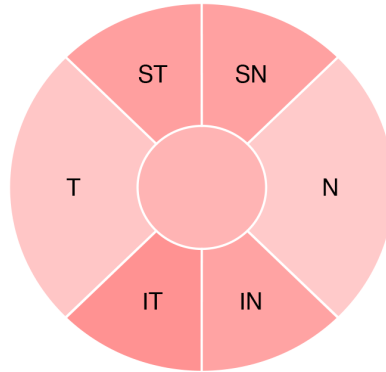
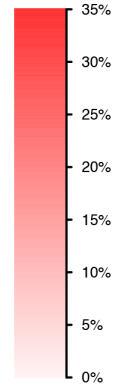
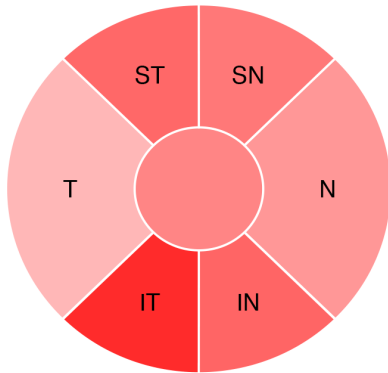
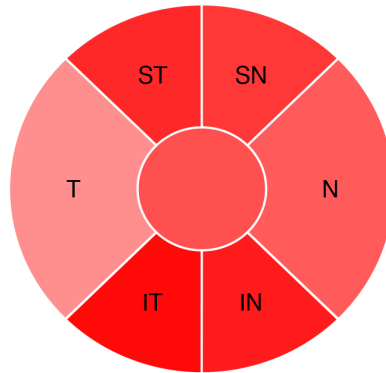
Abbreviations: AL, axial length; BP, blood pressure; CCT, central corneal thickness; cpCD, circumpapillary capillary density; cpRNFL, circumpapillary retinal nerve fiber layer; dB, decibels; FI, focal ischemic; GE, generalized cup enlargement; IOP, intraocular pressure; MD, mean deviation; MOPP, mean ocular perfusion pressure; MY, myopic glaucomatous; PSD, pattern standard deviation; QS: quality score; SS, senile sclerotic disc; VF, visual field; wiCD, whole image capillary density.

Tukey honestly significant difference test $P < 0.05$ for: † GE vs. FI; ‡ GE vs MY; § GE vs SS; || MY vs FI; ¶ SS vs FI; # SS vs MY.

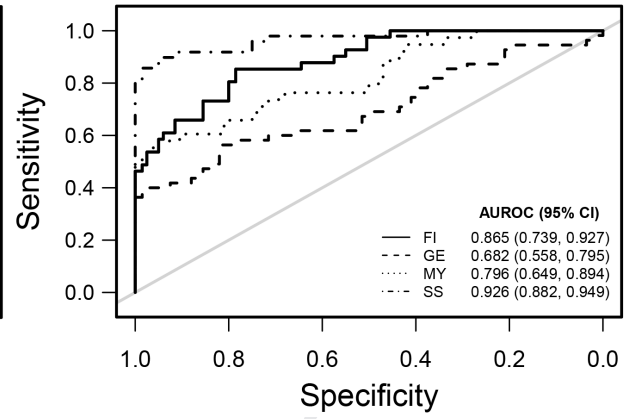
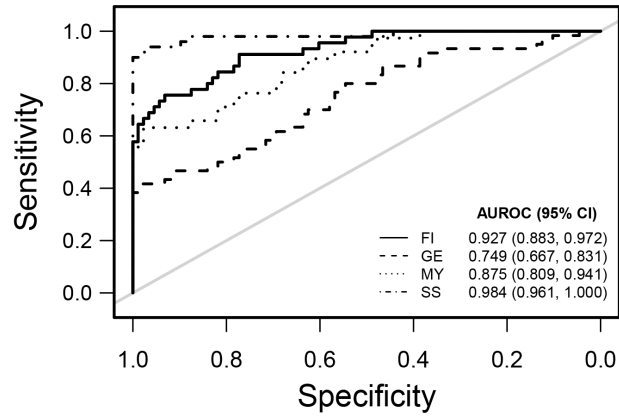
Table3: Factors influencing the cpCD in Glaucoma Patients of Univariate and Multivariate Analysis

	Univariate		Multivariate *	
	B (95% CI)	P-value	B (95% CI)	P-value
Age (per 10 year older)	-1.03 (-2.14, 0.08)	0.068	-0.67 (-1.28, -0.05)	0.035
Gender (female vs. male)	2.73 (0.52, 4.94)	0.016	1.93 (0.91, 2.95)	<0.001
Race (non-African American vs African American)	5.68 (3.46, 7.89)	<0.001	0.62 (-0.67, 1.91)	0.345
IOP (per mm Hg higher)	-0.005 (-0.009, -0.001)	0.013	-0.002 (-0.004, 0)	0.113
Disc Hemorrhage (yes vs no)	-4.73 (-9.76, 0.3)	0.065	-3.6 (-6.02, -1.18)	0.004
MOPP (1 mm lower)	-0.06 (-0.19, 0.07)	0.364	-	-
CCT (per 10 μ m thinner)	-0.13 (-0.43, 0.18)	0.408	-	-
AL (per 1 mm higher)	-0.74 (-1.75, 0.28)	0.153	-	-
VF MD (per 1 dB lower)	-0.68 (-0.83, -0.53)	<0.001	-0.34 (-0.45, -0.23)	<0.001
cpRNFL (per 1 μ m lower)	-0.37 (-0.41, -0.33)	<0.001	-0.28 (-0.32, -0.23)	<0.001
<i>Phenotypes</i>				
SS vs. GE	-8.42 (-10.97, -5.87)	<0.001	-1.91 (-3.48, -0.33)	0.018
SS vs. FI	-4.73 (-7.29, -2.17)	<0.001	-1.45 (-2.82, -0.08)	0.038
SS vs. MY	-5.05 (-8.08, -2.03)	0.001	-1.75 (-3.16, -0.33)	0.016
Quality Score (per 1 score lower)	-0.60 (-1.52, 0.32)	0.202	0.33 (-0.02, 0.68)	0.061
Abbreviations: AL, axial length; BP, blood pressure; CCT, central corneal thickness; cpCD, circumpapillary capillary density; cpRNFL, circumpapillary retinal nerve fiber layer; dB, decibels; FI, focal ischemic; GE, generalized cup enlargement; IOP, intraocular pressure; MD, mean deviation; MOPP, mean ocular perfusion pressure; MY, myopic glaucomatous; PSD, pattern standard deviation; SS, Senile sclerotic disc; VF, visual field; wiCD, whole image capillary density.				



Phenotype: FI**Phenotype: GE**ONH Vessel Density
% Loss**Phenotype: MY****Phenotype: SS**

Journal



Journal Pre-proof

Capillary Density Measured by OCT Angiography in Glaucomatous Optic Disc Phenotypes

Synopsis: This cross-sectional study demonstrates that the discriminating ability of optical coherence tomography angiography parameters to detect glaucoma is influenced by optic disc phenotype and clinicians should be aware when evaluating patients for glaucoma.

Journal Pre-proof